

CHRONIC COUGH CAUSED BY PERICARDIAL CYST LOCATING OUTSIDE THE MEDIASTINUM

Zannat Ekram, DO, Madia Ampey, MD, Vijay Kodadhala, MD, Andrew Berman, MD

RUTGERS UNIVERSITY – NEW JERSEY MEDICAL SCHOOL, NEWARK, NEW JERSEY



Introduction

Pericardial cysts are rare benign lesions usually located in middle mediastinum. They can be asymptomatic or present with atypical chest pain, dyspnea, and persistent cough [1]. We report a rare case of pericardial cyst locating outside the mediastinum making the diagnosis a challenging one.

Case History

A 40-year-old woman with a history of asthma and recurrent pneumonias presented with a productive cough, pleuritic chest pain and fever. The patient reported prior episodes of pneumonias that resolved with antibiotics.

Physical exam findings included T 101F, HR 118/min, BP 121/80 mm of hg, RR 20/min, SpO2 98% on room air and decreased breath sounds in right lower lung zones.

Laboratory results were notable for leukocytosis, negative viral respiratory panel, QuantiFERON gold, and HIV tests.

Patient was started on antimicrobial coverage for presumed pneumonia.

Image studies were suggestive of loculated pleural effusion for which she underwent an unsuccessful attempt of drainage with IR.

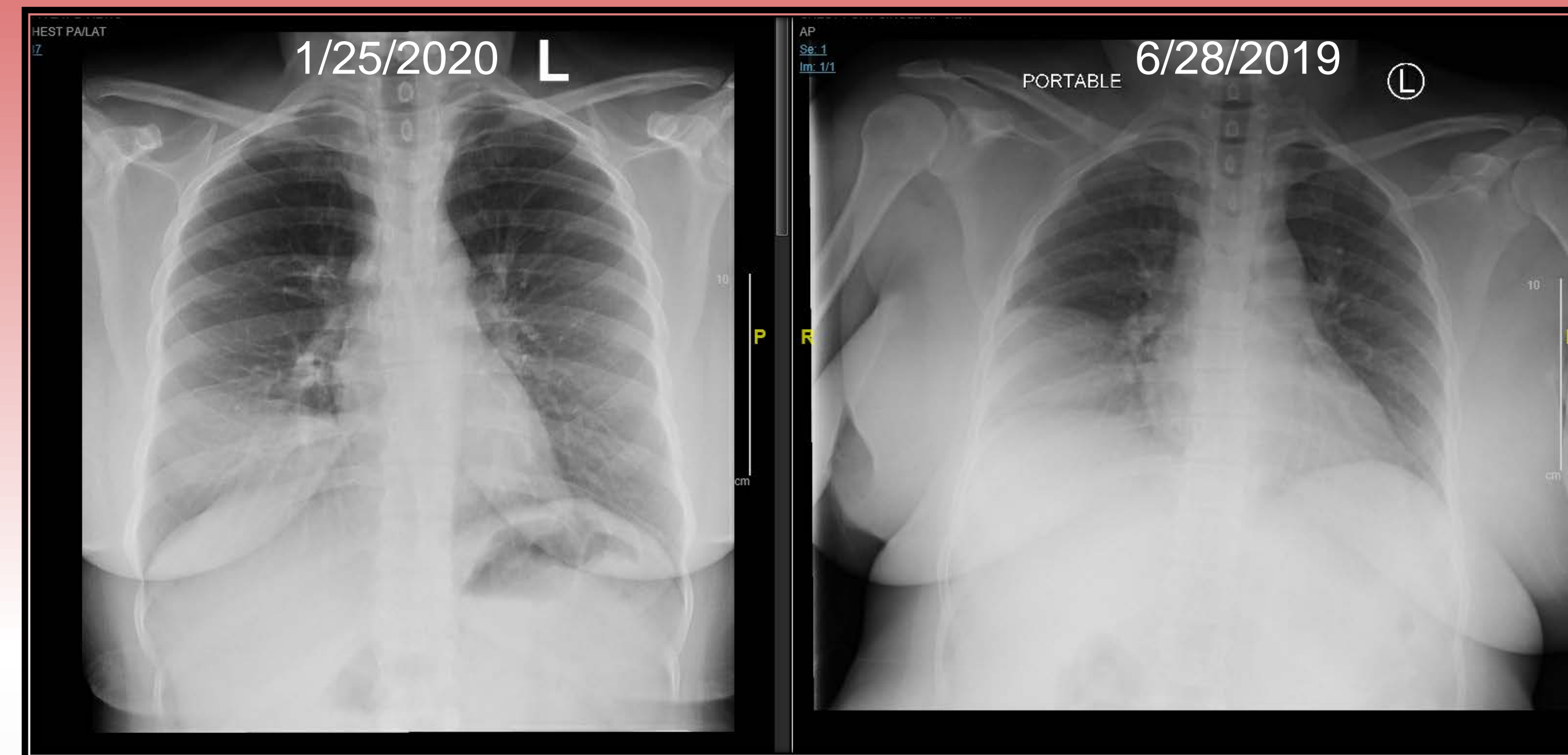


Figure 1: CXR from 7 months ago (Right) and CXR on admission (Left)

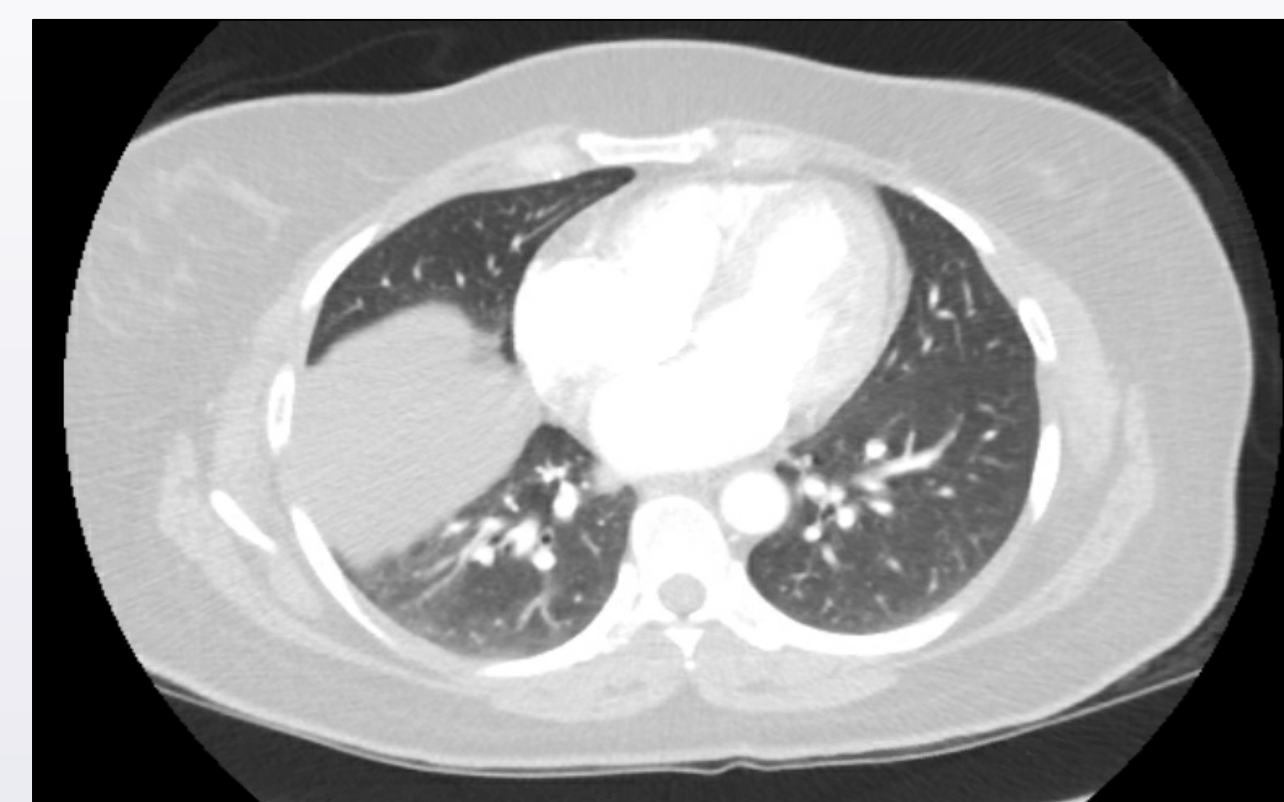

Figure 2: CT chest

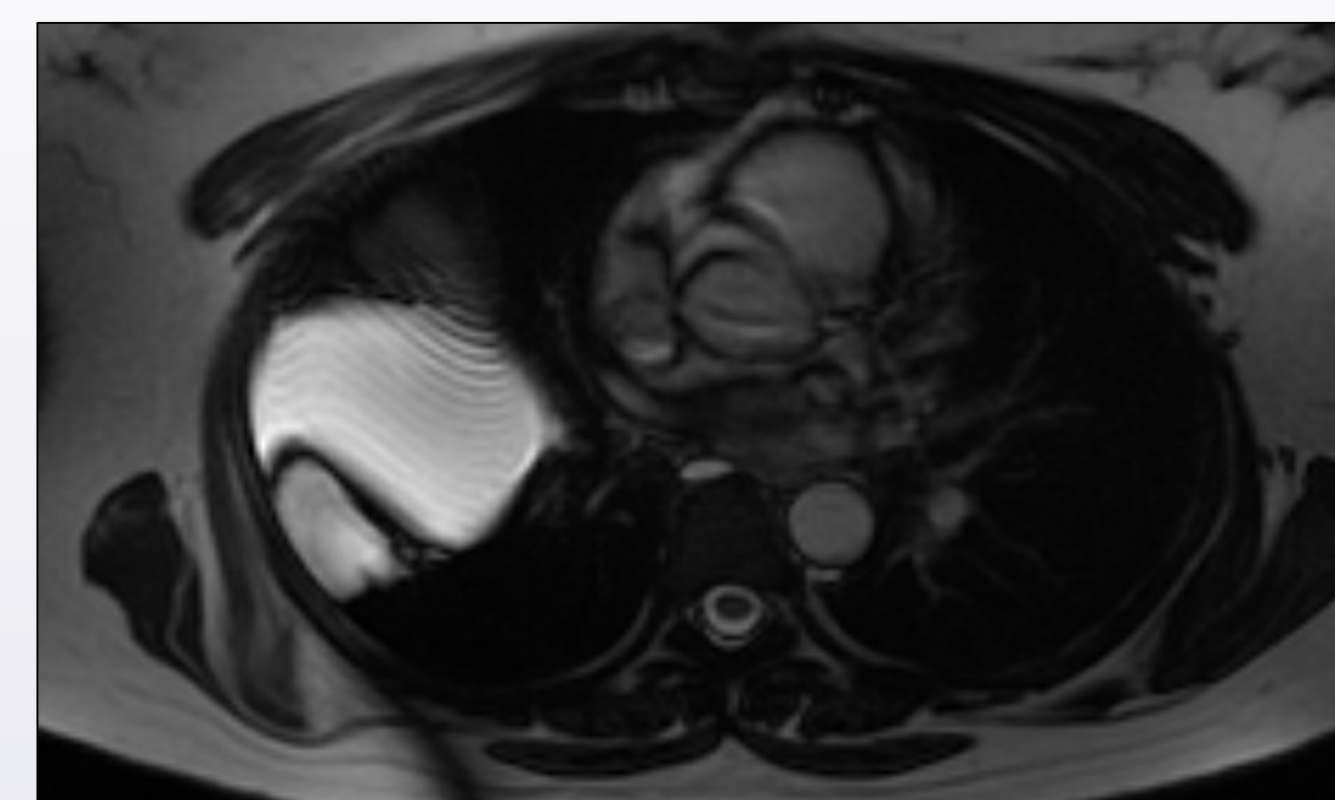


Figure 3: MRI chest

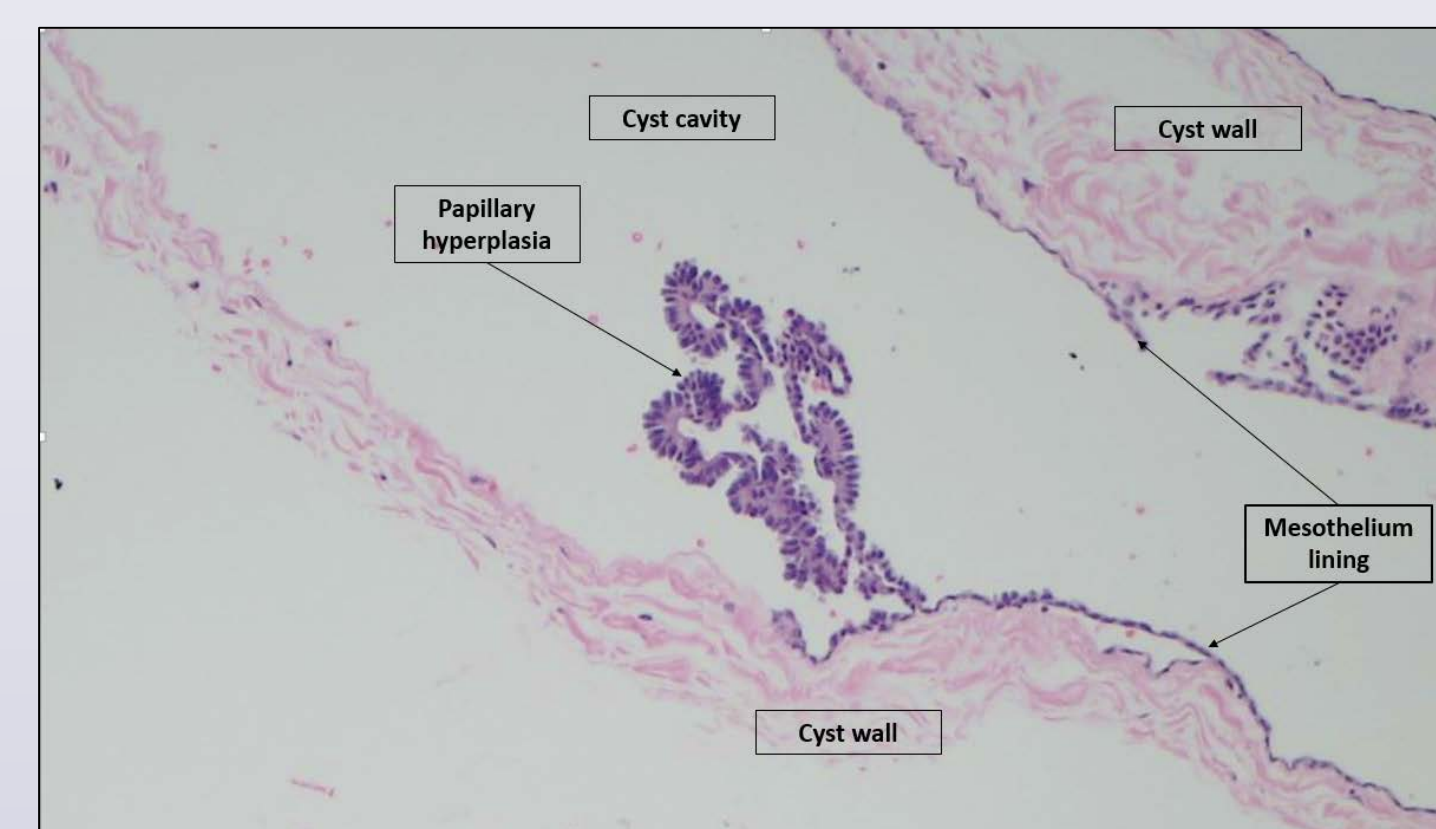


Figure 4: Pathology revealed benign mesothelium-lined cyst with minute foci of papillary hyperplasia compatible with pericardial cyst.

Image Findings

Chest X-ray revealed hazy opacities in the right lower lobe and atelectasis in the right middle lobe that were seen on a prior CXR from 4 weeks and 7 months ago (Figure 1). CT chest with PE protocol revealed “low-attenuation cystic structure along the anterior aspect of the right major fissure” (Figure 2). MRI chest demonstrated loculated fluid with possible septations in the right major fissures consistent with a pseudotumor (Figure 3).

Diagnosis

The patient then underwent VATS procedure which revealed a pericardial cyst which was resected successfully.

Discussion

The incidence of pericardial cyst is 1 in 100,000 [1]. They are usually located in the right cardiophrenic triangle (75%), and less frequently in the left cardiophrenic triangle (22%) or other parts of the mediastinum [3]. Our case was unique because the pericardial cyst was found in the right major fissure outside the mediastinum. CT and echocardiography are the routine diagnostic modalities [1,2]. However, they are not the definitive diagnostic tests, such as was the case with our patient.

Conclusion

Pericardial cyst is a rare congenital anomaly and is in the differential diagnosis for an uncharacteristic cystic structure where diagnosis is unclear from CT and MRI. VATS should be considered as a diagnostic and therapeutic consideration.

References

1. Patel J, Park C, Michaels J, Rosen S, Kort S. Pericardial cyst: case reports and a literature review. *Echocardiography*. 2004;21(3):269-272.
2. Demos TC, Budorick NE, Posniak HV. Benign mediastinal cysts: pointed appearance on CT. *J Comput Assist Tomogr*. 1989;13(1):132-133.
3. Borges AC, Gellert K, Dietel M, Baumann G, Witt C. Acute right-sided heart failure due to hemorrhage into a pericardial cyst. *Ann Thorac Surg*. 1997;63(3):845-847.